



PATIENT

Bruschi Rhett

SPECIES

Canine

BREED

Shih Tzu

SEX

Male Intact

AGE

15.10 years

WEIGHT

17.7lbs

PRESENTING CLINICAL SIGNS

History: Grade II/VI heart murmur. Chronic cough. Mild bronchial disease. Grade IV dental disease. On Hydrocodone 2.5 mg BID. BP: 117mmHg.

ECHOCARDIOGRAM FINDINGS

2D, m-mode, color flow and Doppler imaging is available.

Left ventricle: The LV diameter is normal with adequate myocardial function. LV wall thicknesses are normal.

Left atrium: The left atrium is normal.

Mitral valve: The mitral valve is mildly thickened with no prolapse into the left atrial lumen. Moderate eccentric mitral regurgitation with a normal velocity.

Aortic valve/aorta: The aortic valve is normal in morphology and mobility. Normal aortic outflow velocity; laminar flow. No aortic insufficiency.

Right ventricle: Normal right ventricular diameter and morphology indicating no overt evidence of pulmonary arterial hypertension.

Right atrium: Normal RA dimension.

Tricuspid valve: The tricuspid valve appears normal with moderate tricuspid regurgitation; normal velocity.

Pulmonic valve/pulmonary artery: The pulmonic valve is normal in morphology and mobility. No pulmonic insufficiency. Normal RVOT velocity; laminar flow.

Pericardium/other: No pericardial or pleural effusion noted. No obvious cardiac masses.

Heart rhythm: ECG reveals a sinus rhythm with an average HR of 120bpm.

INTERPRETED BY

Maggie Machen
Lamy, DVM
DACVIM (Cardiology)

IMAGING

PERFORMED BY

Pamela Harrigan,
RDCS

HOSPITAL NAME

Mendon Animal Clinic

REFERRING VET

Dr. Cervasio

INVOICE

31825

DATE

7/13/23

2-Dimensional Measurements

Ao diam (cm)	1.5
LA diam (cm)	1.7
LA:Ao (Swe)	1.1
IVS thickness (cm)	0.8
LVID diastole (cm)	2.5
PW thickness (cm)	0.8
LVID systole (cm)	1.1
FS (%)	56

Doppler Measurements

PV Vmax (m/s)	
AoV Vmax (m/s)	0.96
MR Vmax (m/s)	5.5
TR Vmax (m/s)	2.0
TR PG (mmHg)	18

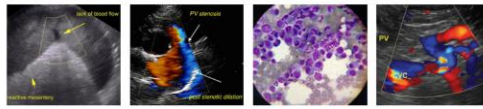
INTERPRETATION OF THE FINDINGS

The cause of the murmur is chronic degenerative valve disease causing moderate mitral and tricuspid regurgitation. Despite significant leaks, the overall cardiac dimensions and functions are normal. No pulmonary hypertension is noted secondary to bronchitis. Monitor for this development, most commonly seen as exertional syncope or dyspnea.

Assessment of progression in the future will help predict long term prognosis, which is highly variable at this stage (B1).

RECOMMENDATIONS

- In a dog without significant left atrial enlargement, no cardiac medications are clearly indicated.
- Omega fatty acid supplementation and mild salt restriction may be of some long-term benefit.



PATIENT

Bruschi Rhett

SPECIES

Canine

BREED

Shih Tzu

SEX

Male Intact

AGE

15.10 years

WEIGHT

17.7lbs

INTERPRETED BY

Maggie Machen
 Lamy, DVM
 DACVIM (Cardiology)

IMAGING

PERFORMED BY

Pamela Harrigan,
 RDCS

HOSPITAL NAME

Mendon Animal Clinic

REFERRING VET

Dr. Cervasio

INVOICE

31825

DATE

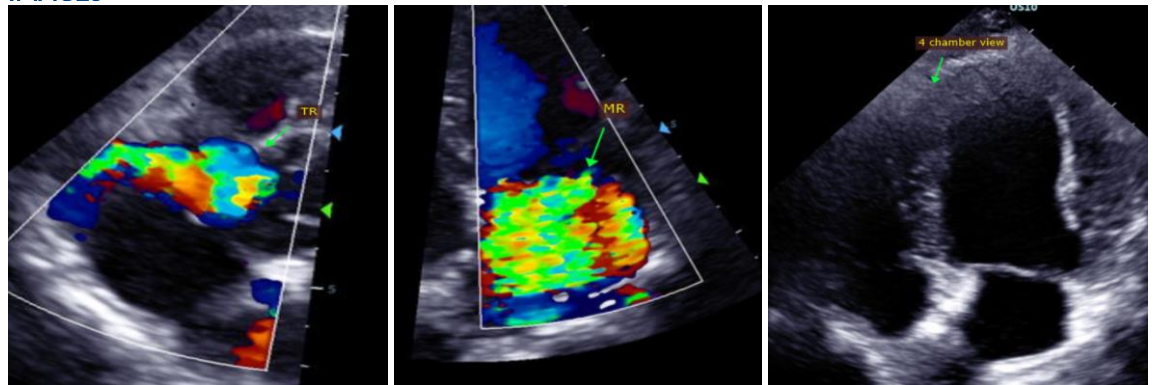
7/13/23

- Anesthetic risk is considered mild if needed. Cardiac protective drug choices (opioid/benzodiazepine premedication, propofol or alfaxalone induction, isoflurane gas) are recommended. Pre-oxygenate for 5-10 minutes prior to induction. Monitor for arrhythmias, hypotension, and hypoxia both intra and post-operatively and intervene as necessary. Mild IV fluid restriction is recommended to avoid fluid overload. Avoid heart rate stimulating drugs such as atropine unless clinically indicated.
- Monitor for development of a cough, labored breathing, exercise intolerance or collapse episodes.

PLAN

- Recommend conservative monitoring with a recheck echocardiogram in 6 months, sooner if any development of clinical signs.

IMAGES



The information and recommendations provided are based on the images presented by the referring veterinarian. No evaluation can be communicated regarding pathology that was not visible in the image/video clips provided.

Thank you for this referral. This report was generated using transcription software, and minor dictation errors may be present. If the clinical or image interpretation does not parallel your findings or if I can be of any further assistance, please contact me.

Maggie Machen Lamy, DVM
Diplomate of the American College of Veterinary Internal Medicine (Cardiology)
 info@sonopath.com

Echocardiogram performed by: Pamela Harrigan, RDCS
 Pet Animal Ultrasound Service (4paus.com)